


Testis

NAACCR 2018-2019 WEBINAR SERIES

1




Q&A

Please submit all questions concerning the webinar content through the Q&A panel.





If you have participants watching this webinar at your site, please collect their names and emails

We will be distributing a Q&A document in about one week. This document will fully answer questions asked during the webinar and will contain any corrections that we may discover after the webinar.


2



Fabulous Prizes

3



Guest Speakers

Louanne Currence, RHIT, CTR

Denise Harrison, BS, CTR






Agenda


Anatomy

Solid Tumor Rules

Staging

- AJCC
- Summary Stage
- EOD
- SSDI



TESTICULAR CANCER
Where the Boys Are

Louanne Currence, RHIT, CTR
Denise Harrison, BS, CTR

Case Study #1: Workup

- 42 yr old male noticed palpable Lt testicular mass. CXR, CT scan abd/pelvis, and screening serum testicular cancer tests negative.
- Sonogram: mult. areas hypoechoic heterogeneity; overall diameter 2.5 cm; appearance suspicious for malignancy
- Pre-op markers: AFP 2 ng/mL (normal 0 – 9); BHCG < 2 mIU/mL (normal < 2); LDH 197 units/L (normal 100 – 230).

7

Case Study #1: CAP Checklist

- SPECIMEN TYPE: radical orchiectomy
- SPECIMEN LATERALITY: Left
- TUMOR FOCALITY: Unifocal
- TUMOR SIZE: 1.8 cm in greatest dimension of tumor
- MACROSCOPIC EXTENT OF TUMOR: Confined to testes
- HISTOLOGIC TYPE: Seminoma, classic type
- SPERMATIC CORD: Uninvolved by tumor
- MICROSCOPIC TUMOR EXTENSION: None identified
- LYMPHOVASCULAR INVASION: Absent
- PATHOLOGIC STAGING:
 - Primary tumor: pT1a, tumor limited to testes
 - Regional lymph nodes: pNX

8

Case Study #1: Post-Op

- Post-op lab markers: per urologist not required since they were negative prior to surgery.
- POSTOP RAD ONC CONSULTATION: Here to discuss treatment options; given his disease stage, we discussed recurrence potential of ~15 to 20%; discussed alternatives of observation alone, adjuvant radiation therapy, or single-agent carboplatinum.
- Postop adjuvant RT: 22.5GY peri-aortic lymph nodes, 18MV photons

9

Case Study #2: Workup

- Here for scrotal swelling; mass on Lt side has grown in size and is painful; hx of hernial repair and varicocele repair at age 14.
- Sonogram: 8.1 cm Lt testicular mass concerning for malignancy
- Pre-op Labs: AFP 4.7 ng/mL (normal 0 – 8); BHCG: 51.48mIU/mL (< 5000 mIU/mL); LDH 1447 IU/L (313 – 618 IU/L)

10

Case Study #2: CAP Checklist

- SPECIMEN TYPE: radical orchiectomy
- SPECIMEN LATERALITY: Left
- TUMOR FOCALITY: Multifocal (two foci of 5 cm and 2.7cm)
- TUMOR SIZE: 5 cm and 2.7 cm in greatest dimension of tumors
- MICROSCOPIC EXTENT OF TUMOR: Confined to the testis
- HISTOLOGIC TYPE: Mixed germ cell tumor: Embryonal carcinoma (85%), Seminoma (10%, Yolk sac tumor (5%)
- MARGINS: Spermatic cord margin and other margins: Uninvolved by tumor
- MICROSCOPIC TUMOR EXTENSION: Not identified
- LYMPH-VASCULAR INVASION: Indeterminate (see comment)

11

Case Study #2: continued

- PATHOLOGIC STAGING
 - TNM descriptors: m(multiple)
 - Primary tumor: pT1(m): Tumor limited to the testis and epididymis without definitive vascular/lymphatic invasion
 - Regional lymph nodes: pNX: Cannot be assessed (no nodes submitted or found)
- SERUM TUMOR MARKERS: At least S1
 - AFP 4.7 ng/mL (normal 0 – 8); BHCG: 51.48mIU/mL (< 5000 mIU/mL); LDH 1447 IU/L (313-618 IU/L)

POST-OP LABS: AFP 3.2 ng/mL (normal 0 – 8); BHCG < 2.39 mIU/mL (normal 0 – 1); LDH 412 IU/L (normal 313 – 618 IU/L)

12

Case Study #3: Workup

- 34 year old male in E.R. with large very firm testicular tumor about 9 cm in size, consistent with possible malignancy by exam and ultrasound.
- Pre-op labs: AFP = 83 (H), BHCG 3 mIU/mL (normal 0 – 5); LDH 293 u/L (normal 100 – 230)

13

Case Study #3: CAP Checklist

- SPECIMEN TYPE: radical orchiectomy
- SPECIMEN LATERALITY: Left
- TUMOR FOCALITY: Unifocal
- TUMOR SIZE: 9.5 x 7.9 x 6.4 cm
- MICROSCOPIC EXTENT OF TUMOR: Confined to the testis
- HISTOLOGIC TYPE: Teratoma (90%) and yolk sac tumor (10%) with focal rhabdomyosarcomatous differentiation
- MARGINS
 - Spermatic cord margin: Uninvolved by tumor
 - Other margins: Uninvolved by tumor
- LYMPH-VASCULAR INVASION: Present
- PATHOLOGIC STAGING
 - Primary tumor: pT2
 - Regional lymph nodes: pNX

14

Case Study #3: Post-op

- Post-op CT Abd/Pel: prominent 3.3 cm para-aortic and 1.3 cm aortocaval LNs concerning for metastatic dz; Additional Rt retrocrural LN, 1.6 cm subcarinal/paraesophageal LN, soft tissue nodule in periphery of RLO and nodular area of pleural thickening in medial aspect Lt lung base suspicious for additional areas of metastatic dz
- Post-op markers: AFP = 193 (H), LDH = 201 (normal), BhCG not repeated

15

Case Study #3: Post-op, continued

- Med onc Consult: Good risk, nonseminomatous, Lt testicular mixed germ cell carcinoma. Plan: 3 cycles of BEP (Bleomycin, Etoposide, Cisplatin) after he heals from surgery followed by excision of metastatic tissue in 3-stage
- 6/19/XX: chemo started
- 9/27/XX: Mediastinal LND and removal of pulmonary mets
- 11/19/XX: Rt RPLND: 0/4 periaortic, 1/7 interaortocaval LNs
- 2/12/YY: Lt RPLND: 3/5 paracaval LNs in 8.8 cm mass

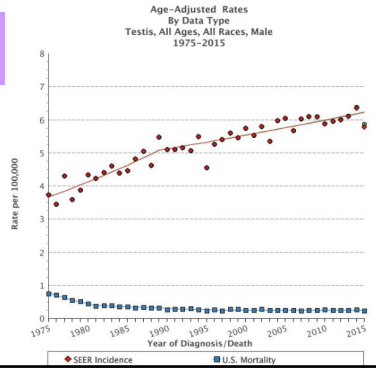
16

Testicular Cancer Facts

- 1% of all male cancer
 - About 8,000 new cases a year
 - 390 deaths per year
- Most common cancer ages 15-34
- Usually white males, especially Scandinavian
- 1-3% bilateral
- 90% curable – even in late stage

17

SEER Data



Risk Factors

- Cryptorchidism
- Congenital abnormalities
 - Testes, penis, or kidneys
 - Inguinal hernia
- History of testicular cancer
- Family history (father, brother)
- Genetics: TGCT1 found

19

Incidence Rate by Race (U.S.A.)

RACE/ETHNICITY	RATE
White	6.8 per 100,000 men
Black	1.54 per 100,000 men
Asian/Pacific Island	2.2 per 100,000 men
Amer Indian/Alaskan	5.4 per 100,000 men
Hispanic	5.1 per 100,000 men

NCI's SEER Cancer Statistics Review 2010 - 2014

20

Screening

- Not recommended
 - Good survival rate, even at later stage
 - Not cost-effective
- Testicular Self-Exam
 - After shower
 - Roll both
 - Check epididymis

The best time to check your testicles is in the shower.

MAN UP CHECK'EM

JUST FOLLOW THESE SIMPLE STEPS:

- 1 Check one testicle at a time.
- 2 Hold the testicle between your thumbs and fingers of both hands and roll it gently between your fingers.
- 3 If you notice any of these symptoms...
 - hard lumps
 - smooth or rounded lumps
 - changes in size, shape, or consistency
 ...see a urologist right away.

21

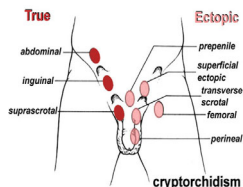
Symptoms

- Painless lump or swelling
- Pain or discomfort
- Enlargement, "funny" feeling
- Heaviness in scrotum
- Dull ache in back, groin, or abdomen
- Fluid collection in scrotum
- Enlargement/tenderness breasts

22

Topography Codes

- C62.0 Undescended
- C62.1 Descended
- C62.9 Testis NOS
 - Unknown if descended



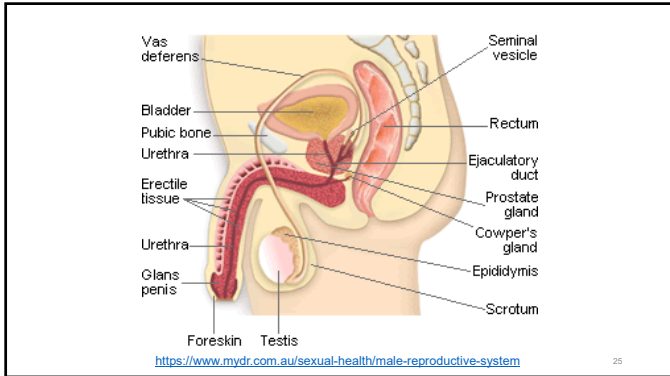
<https://embryology.med.unsw.edu.au/embryology/index.php>

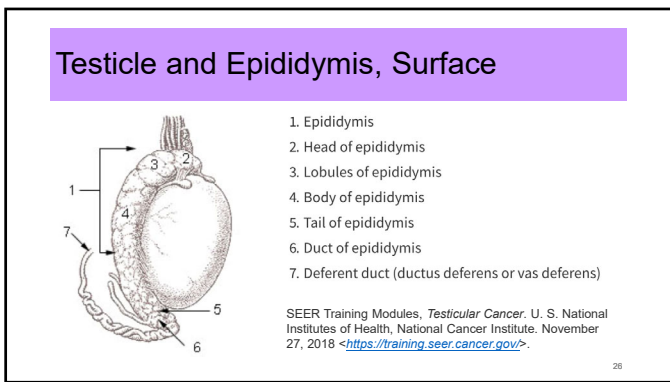
23

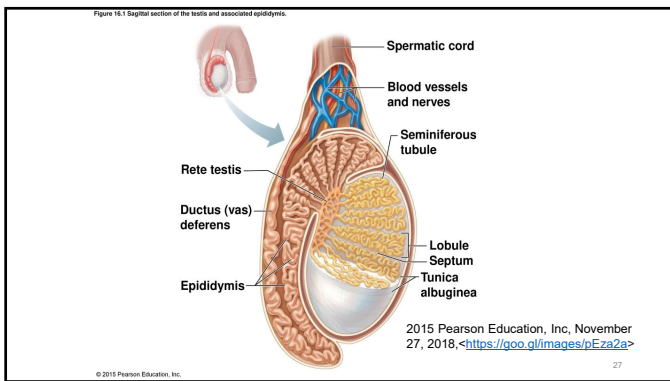
Vocabulary

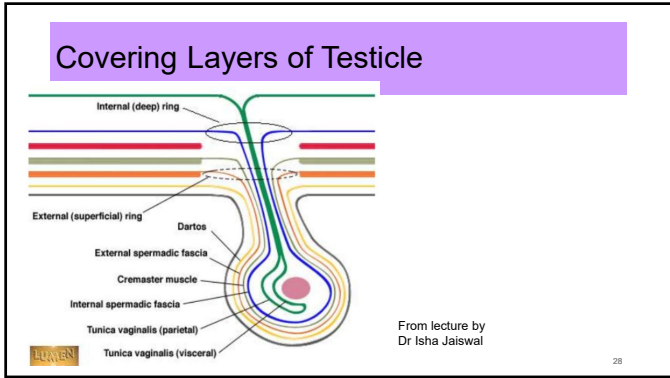
- **Leydig cells** – secrete testosterone
- **Sertoli cells** – nurse or mother cells; nourish the developing sperm cells through the process of spermatogenesis
- **Tunica albuginea** – dense capsule around each testis; inhibits direct extension of tumor
- **Rete (ree' tee) testis** – network of efferent ducts
- **Epididymis** – storage vessel for sperm; long, coiled tube external to testis
- **Vas (ductus) deferens** – muscular extension of epididymis which carries sperm to urethra

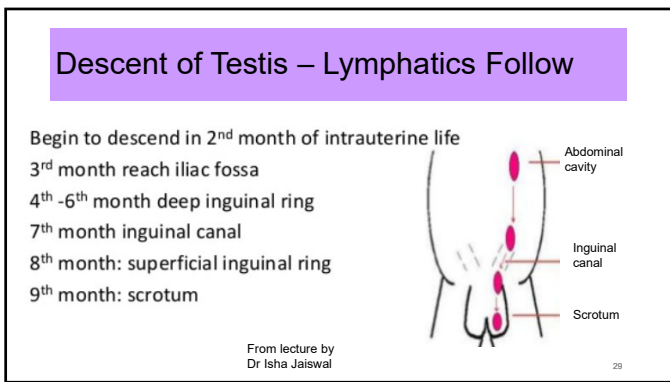
24

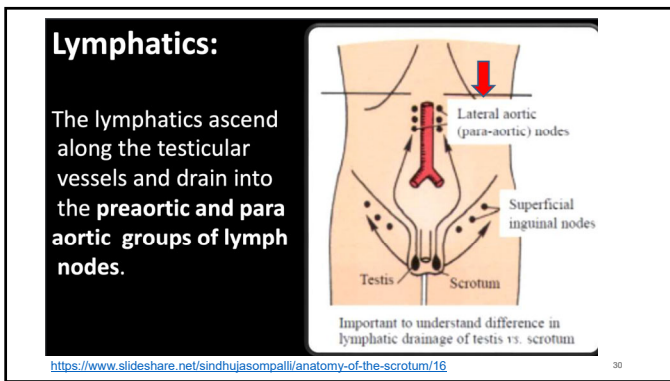












Workup

- Tumor markers pre-op
 - LDH, AFP, βHCG
- Ultrasound
- Biopsy (not usually of testicle to avoid scrotal contamination)
- Chest x-ray and other radiology for staging

31

MP/H Rules – Other Sites

- **Rule M8** Tumors on **both sides** (right and left) of a site listed in Table 1 are multiple primaries. (C62 YES)
- **Rule M10** Tumors diagnosed **more than one (1) year** apart are multiple primaries.
- **Rule M17** Tumors with ICD-O-3 **histology** codes that are **different** at the first (xxxx), second (xxxx) or third (xxxx) number are multiple primaries.

32

Number of Primaries

- **Case 1:** Orchiectomy path states unifocal
- **Case 2:** Orchiectomy path states multifocal (two foci)
- **Case 3:** Orchiectomy path states unifocal

33

Number of Primaries

- Case 1 _____
- Case 2 _____
- Case 3 _____

34

Rule H5, H16, H30 – Table 2

Column 1: Required Histo	Column 2: Combined w/Histo	Column 3: Combination Term	Column 4: Code
Teratoma	Embryonal carcinoma	Teratocarcinoma	9081
Teratoma & one or more of histologies in Col 2	Seminoma Yolk sac tumor	Mixed germ cell tumor	9085
Choriocarci- noma	Teratoma Seminoma Embryonal	Choriocarcinoma combined w/other germ cell elements	9101

35

Histology

- **Case 1:** Seminoma, classic type
- **Case 2:** Mixed germ cell tumor
 - Embryonal carcinoma (85%)
 - Seminoma (10%)
 - Yolk sac tumor (5%)
- **Case 3:** Teratoma (90%) and yolk sac tumor (10%) with focal rhabdomyosarcomatous differentiation

36

Histology

- Case 1 _____
- Case 2 _____
- Case 3 _____

37


Germ Cell Tumors

- CIS
- Seminoma
 - Seminoma with syncytiotrophoblastic cells
- Spermatocytic tumor (formerly spermatocytic seminoma)
- Embryonal carcinoma
- Yolk sac tumor
- Teratoma
- Choriocarcinoma

38

Seminoma

- 75% stage I
- 4-5th decade at diagnosis
- Mets to LNs
- Negative AFP (for pure seminoma)



medstat.med.utah.edu

39

Nonseminomatous Germ Cell Tumors

	Embryonal	Yolk Sac	Choriocarcinoma	Teratoma
Age	30s	Children Adults	25-30s	Children 20-30s
Pure	2%	Children	Rare (poor prognosis)	5%
Mixed	Usually	Adults	Usually	Usually
Mets	Liver, RLNs, lung	Liver	Lung, liver, brain	
AFP	(+) focal	(+)	(-)	(-)
βhCG	(-)	(-)	(+) (>100K mIU/ml)	(-)
CEA	(-)			

Nongerminial Tumors

Sex Cord Stromal Tumors

- **Leydig cell**
 - Median age 60 yrs
 - Rarely metastasize
 - Sx: Endocrine abnormalities
- **Sertoli cell**
 - Any age
 - Only 10% malignant
- **Granulosa cell**
 - Juvenile - benign
 - Adult - rare

Nongerminial Tumors, cont.

- **Gonadoblastomas**
 - Mixed germ cell & sex cord tumor
 - Occurs in undescended
 - Bilateral 30%
 - Benign BUT path should be reviewed for malignant germ cell
- **Lymphomas & leukemias**
 - Late manifestation of disseminated disease
 - Common in children with ALL

Others

- Rhabdomyosarcoma
 - Most common sarcoma in children
 - Can originate in testicle
- Metastatic – 2.5% men
- Extragonadal Germ Cell Tumors
 - Usually mediastinal, retroperitoneal, or pineal
 - May have CIS in testicle if retroperitoneal

43

Grade Time Frame Guidelines

- **Grade Clinical**
 - Info during "clinical" time frame
 - Usually bx or FNA
 - Before any treatment
- **Grade Pathological**
 - Info from resected tumor
 - UNLESS clinical grade is higher/worse
- **Grade Post-Therapy**
 - Info from resected tumor POST neoadjuvant

Resection must meet AJCC criteria for cancer site

44

Grade Clinical Guidelines

- Microscopic exam is done (FNA, biopsy, needle core biopsy, etc.)
- Cannot be BLANK
- Assign highest grade from primary tumor during clinical time frame
- Code 9 (unknown) when:
 - Grade not documented
 - Clinical staging N/A
 - Grade checked N/A on CAP Protocol
- If only 1 grade available, and unknown grade time frame, assign to grade clinical

45

Grade Pathological Guidelines

- Surgical resection done
- MUST not be BLANK
- Assign highest grade from PRIMARY tumor
 - Use clinical grade when resection performed and:
 - **Clinical grade is higher**
 - **No grade documented**
 - **No residual tumor**
- *Bx T4/Bx LN: eligible for path stage in AJCC, cannot use for grade path because NO resection*

46

Grade Pathological Guidelines

- Code 9 (unk) when:
 - Grade not documented (and no clinical grade)
 - No resection of primary site
 - Neoadjuvant therapy done (see Post-Tx Grade)
 - Clinical case only
 - Only one grade documented and can't tell if clinical or pathological (put in clinical)
 - Grade checked N/A on CAP Protocol

47

Grade Post-Therapy Guidelines

- Leave **BLANK** when:
 - No neoadjuvant therapy
 - Clinical or pathological case only
 - Only one grade and can't tell which one – code to clinical
- Assign highest grade from resected primary AFTER neoadjuvant therapy
- Code 9 (unk) when surgical resection performed post neoadjuvant treatment, **and**:
 - Grade from primary not documented
 - No residual tumor
 - Grade checked N/A on CAP Protocol

48

Grade ID Table 98

Code	Description
A	Well differentiated
B	Moderately differentiated
C	Moderately differentiated
D	Undifferentiated, anaplastic
9	Grade cannot be assessed; Unknown

Note: No grade items on CAP Protocol forms/instructions

49

Grade Fields

- **Cases 1-3** : Clinical – no microscopic examination
 Pathological – no grade provided
 Post-Therapy – no neoadjuvant treatment

50

Grade Fields

Clinical Pathological Post Therapy

- Case 1 _____ _____ _____
- Case 2 _____ _____ _____
- Case 3 _____ _____ _____

51

Timing for Tumor Size

Clinical Size (SEER)

Largest size in mm

- Before ANY treatment starts

OR

- Within 4 months diagnosis date if no treatment (incl observation, supportive care)

OR

- To date of cancer progression if happens before 4-month window

Pathological Size (SEER)

Largest size in mm of primary tumor that has been resected (including after neoadjuvant therapy) as part of the first definitive treatment

TS Summary

Best TS **prior to** neoadjuvant therapy

Surgical size = Clinical size

52

Recording Tumor Size

Code	Tumor Size Description
000	No mass/tumor found
001	1 mm or < 1 mm
002 – 988	Exact size in mm (2 mm to 988 mm)
989	≥ 989 mm
990	Microscopic focus or foci only and no size focus given
999	Unknown; size not stated; not documented in patient record; size tumor cannot be assessed; not applicable

53

Tumor Size fields

- **Case 1:** **Sonogram:** mult. areas hypoechoic heterogeneity; overall diameter 2.5 cm; appearance suspicious for malignancy
Path: 1.8 cm in greatest dimension of tumor; additional dimensions 1.6 x 1.4 cm
- **Case 2:** **Path:** Main tumor mass: 5 cm; additional tumor nodule: 2.7 cm
- **Case 3:** **H&P:** large very firm testicular tumor about 9 cm in size, consistent with possible malignancy by exam and ultrasound. **Path:** 9.5 x 7.9 x 6.4 cm

54

Tumor Size Fields

	Clinical	Pathological	Summary
• Case 1	_____	_____	_____
• Case 2	_____	_____	_____
• Case 3	_____	_____	_____

55

Lymphovascular Invasion

- Record from
 - path report or physician statement
 - Any primary tumor specimen: biopsy or resection
- Code 0 for benign, borderline, in situ
- Special instructions (use the table) for pts treated with neoadjuvant therapy

56

Lymphovascular Invasion, cont.

- Code 1 (LVI NOS) when:
 - LVI or one of its synonyms is present
 - Synonyms (not an exhaustive list)
 - Angiolymphatic invasion
 - Blood vessel invasion
 - Lymph vascular emboli
 - Lymphatic invasion
 - Lymphovascular invasion
 - Vascular invasion

57

Lymphovascular Invasion, cont.

Code 8	Code 9
Lymphoma	No micro exam of primary tumor tissue
HemeRetic	Primary site specimen is Cytology or FNA
Plasma Cell Myeloma	Bx is very small tissue sample
Schemas other than Penis and Testis IF the registry is not collecting LVI (standard setter does not require it)	Not possible to determine LVI
	Pathologists states specimen insufficient to determine LVI
	LVI not mentioned in path rpt
	Primary site unknown

Lymphovascular Invasion Codes

- 0 LVI not present, not identified (includes in situ, benign, and borderline)
- 1 LVI present/identified, NOS
- 2 Lymphatic & small vessel invasion only (L)
- 3 Venous (large vessel) invasion only (V)
- 4 BOTH lymphatic & small vessel AND venous large vessel invasion
- 8 Not Applicable
- 9 Presence of LVI unknown

CAP Protocol choices: Not identified, Present, Cannot be determined

Lymphovascular Invasion

- **Case 1:** LVI absent
- **Case 2:** LVI indeterminate
- **Case 3:** LVI present

Lymphovascular Invasion

- Case 1: _____
- Case 2: _____
- Case 3: _____

61

SUMMARY STAGE

SEER Summary Stage 2018

- **0 – In situ, Intraepithelial, noninvasive**
 - Germ cell neoplasia in situ
 - Intratubular germ cell neoplasia
- **1 – Localized only (localized, NOS)**
 - **WITHOUT or UNKNOWN** lymphovascular invasion

Body of testis	Tunica albuginea
Rete testis	Tunica vaginalis involved
Surface implants (surface of tunica vaginalis)	Tunica, NOS

63

SEER Summary Stage 2018, cont.

• 2 – Regional by direct extension only

WITH lymphovascular invasion
Tumor limited to testis (including rete testis invasion)

WITH or **WITHOUT** lymphovascular invasion

Dartos muscle, ipsilateral	Scrotum, ipsilateral
Epididymis	Spermatic cord, ipsilateral
Hilar soft tissue	Vas deferens
Mediastinum (of testis)	Visceral mesothelial layer

64

SEER Summary Stage 2018, cont.

• 3 – Regional lymph node(s) involved only **WITH** or **WITHOUT** previous scrotal or inguinal surgery

Aortic, NOS	Pericaval, NOS
Lateral (lumbar)	Interaortocaval
Para-aortic	Paracaval
Periaortic	Precaval
Preaortic	Retrocaval
Retroaortic	Retroperitoneal, NOS
	Spermatic vein
	Regional LN(s), NOS; LN(s), NOS

65

SEER Summary Stage 2018, cont.

• 3 – Regional lymph node(s) involved only **WITH** previous scrotal or inguinal surgery

- External iliac
- Inguinal node(s), NOS
- Deep, NOS
- Node of Cloquet or Rosenmuller (highest deep inguinal)
- Superficial (femoral)
- Pelvic, NOS

• 4 – Regional by BOTH direct extension AND regional lymph node(s) involved (Codes 2 + 3)

66

SEER Summary Stage 2018, cont.

• 7 – Distant site(s) (including further contiguous extension)

- | | |
|----------------------------|--|
| Adrenal (suprarenal gland) | Distant metastasis, NOS |
| Kidney | Carcinomatosis |
| Penis | Distant metastasis WITH or WITHOUT distant lymph node(s) |
| Retroperitoneum | |
| Scrotum, contralateral | |
| Testis, bilateral | |
| Ulceration of scrotum | |

67

SEER Summary Stage 2018, cont.

• 7 – Distant lymph node(s), cont.

- Deep, NOS
- Node of Cloquet or Rosenmuller (highest deep inguinal)
- Superficial (femoral)
- Pelvic, NOS
- Lymph nodes **WITHOUT** previous scrotal or inguinal surgery or **UNKNOWN** if previous scrotal or inguinal surgery
- External iliac
- Inguinal nodes, NOS

68

Summary Stage 2018

- **Case 1:** Confined to testes; LVI absent
- **Case 2:** Confined to testes; LVI indeterminate
- **Case 3:** Confined to testes; LVI present: post-op scans show involved RLNs (para-aortic and aortocaval), as well as mets to distant LNs (retrocrural and subcarinal/paraesophageal) and bilateral lung mets

69

Summary Stage 2018

- Case 1 _____
- Case 2 _____
- Case 3 _____

70

Extent of Disease

EOD Primary Tumor

Code	Description
000	<ul style="list-style-type: none"> • In situ, intraepithelial, noninvasive • Intra-articular germ cell neoplasia • Germ cell neoplasia in situ
100	<p>FOR PURE SEMINOMAS ONLY</p> <ul style="list-style-type: none"> • Tumor < 3 cm, limited to the testis W/O LVI or unknown if LVI
150	<p>FOR PURE SEMINOMAS ONLY</p> <ul style="list-style-type: none"> • Tumor ≥ 3 cm, limited to the testis W/O LVI or unknown if LVI

Note: radical orchiectomy **required** for codes 100, 200, 400, and 500

72

EOD Primary Tumor, cont.

	Tumor limited to testis W/O LVI or unknown if LVI
200	<ul style="list-style-type: none"> • Body of testis • Rete testis • Surface implants (surface of tunica vaginalis) • Tunica albuginea • Tunica vaginalis involved • Tunica, NOS • Confined to testis, NOS • Localized, NOS
300	Tumor limited to testis (including rete testis invasion) W/ LVI
400	<ul style="list-style-type: none"> • Epididymis • Hilar soft tissue • Mediastinum (of testis) • Visceral mesothelial layer

73

EOD Primary Tumor, cont.

500	<ul style="list-style-type: none"> • Spermatic cord, ipsilateral • Vas deferens
600	<ul style="list-style-type: none"> • Dartos muscle, ipsilateral • Scrotum, ipsilateral
700	<ul style="list-style-type: none"> • Penis • Scrotum, contralateral • Ulceration of scrotum • Further contiguous extension
800	• No evidence of primary tumor
999	• Unknown extension; Primary tumor cannot be assessed; Not documented in patient record; Death Certificate Only

74

EOD Regional Nodes

- Aortic, NOS
 - Lateral (lumbar)
 - Para-aortic
 - Periaortic
 - Preaortic
 - Retroaortic
- Pericaval, NOS
 - Interaortocaval
 - Paracaval
 - Precaval
 - Retrocaval
- Retroperitoneal below the diaphragm or NOS
- Spermatic vein

75

EOD Regional Nodes

- Lymph nodes **WITH** previous scrotal or inguinal surgery
 - External iliac
 - Inguinal nodes, NOS
 - Deep, NOS
 - Node of Cloquet or Rosenmuller (highest deep inguinal)
 - Superficial (femoral)
 - Pelvic

Note: Involvement of inguinal, pelvic, or external iliac LNs **WITHOUT** or **unknown** if previous scrotal or inguinal surgery prior to presentation of the testis tumor is coded in EOD Mets as distant lymph node involvement.

76

EOD Regional Nodes

000	• CLINICAL or PATHOLOGICAL: No RLN involvement
100	• CLINICAL ONLY: Metastasis in LN(s), all < 2 cm
200	• PATHOLOGICAL ONLY: : Metastasis in LN(s), all < 2 cm
300	• CLINICAL ONLY: Metastasis lymph node(s), 2 to 5 cm (inclusive)
400	• PATHOLOGICAL ONLY: Metastasis lymph node(s), 2 to 5 cm (inclusive)
500	• PATHOLOGICAL ONLY: ENE present
600	• CLINICAL or PATHOLOGICAL: Metastasis in a LN > 5 cm
800	• Regional lymph node(s), NOS • Lymph node(s), NOS
999	• Unknown; regional lymph node(s) not stated • Regional lymph node(s) cannot be assessed • Not documented in patient record • Death Certificate Only

77

EOD Mets

Code	Description
00	• No distant metastasis • Unknown if distant metastasis
10	Distant LN(s) W/O or UNKNOWN if previous scrotal or inguinal surgery • External iliac <ul style="list-style-type: none"> • Pelvic, NOS
30	Distant LN(s) W/O or UNKNOWN if previous scrotal or inguinal surgery • Inguinal, NOS <ul style="list-style-type: none"> • Deep, NOS • Superficial (femoral) • Node of Cloquet or Rosenmuller (highest deep inguinal) <ul style="list-style-type: none"> • Distant lymph node(s), NOS • Retroperitoneal specified as above the diaphragm
50	• Lung
60	• Other distant site(s) W/ or W/O/ distant LN(s) and/or lung • Carcinomatosis
70	• Distant metastasis, NOS
99	• Death Certificate Only

78

EOD Fields

- **Case 1:** Pure seminoma confined to testes; LVI absent
- **Case 2:** Mixed germ cell tumor confined to testes; LVI indeterminate
- **Case 3:** Mixed germ cell tumor confined to testes; LVI present: post-op scans show involved RLNs (para-aortic and aortocaval), as well as mets to distant LNs (retrocrural and subcarinal/paraesophageal) and bilateral lung mets; path showed 8.8 cm paracaval LN

79

EOD Fields

	Primary Tumor	Regional Nodes	Mets
• Case 1	_____	_____	_____
• Case 2	_____	_____	_____
• Case 3	_____	_____	_____

80

Survival

Percent of Cases & 5-Year Relative Survival by Stage at Diagnosis: Testis Cancer

Percent of Cases by Stage

Stage	Percent of Cases
Localized (68%)	68%
Regional (18%)	18%
Distant (12%)	12%
Unknown (1%)	1%

5-Year Relative Survival

Stage	5-Year Relative Survival (%)
Localized	99.2%
Regional	96.3%
Distant	73.8%
Unstaged	77.4%

SEER 18 2005-2011, All Races, Males by SEER Summary Stage 2000

TNM Staging

- Changes from the 7th Edition**
- Seminomas use TS
 - 3 cm cut point
 - Invasion of epididymis and hilar soft tissue have changed T definition
 - Spermatic cord involvement could be categorized in T or M, depending on route of involvement
- Review TNM Staging forms*

83

- CAP Testis Protocol Summary of Changes (3/2018)**
- Version 4.0.1.0 errata
 - Size of largest metastatic deposit
 - **MODIFIED** unit of measure from mm to cm
 - Tumor extension
 - **MODIFIED** ____ Tumor invades through tunica albuginea and perforates tunica vaginalis (mesothelium)
 - Primary tumor
 - **MODIFIED** ____ pT3: Tumor directly invades spermatic cord soft tissue with or without lymphovascular invasion

84

Additional Notes (from TNM Supplement for 7th ed. TNM staging)

- pT2: includes invasion of cremaster muscle, cremaster fascia, testicular portion of internal/external spermatic fascia (i.e. invasion scrotum w/o skin)
- pT3: invading spermatic cord means direct invasion. Invasion lymph or blood vessels = vessels lined by endothelium. Includes invasion plexus pampiniformis or invasion perihilar fat
- pT4: invasion subcutis or cutis of scrotum

85

More Notes (TNM Supplement for 7th ed TNM staging)

- Tis – can be diagnosed in case of testis biopsy with intratubular germ cell neoplasia (carcinoma in situ)
- T4 – can be diagnosed if scrotum invasion is confirmed by biopsy

86

N Categories

- Very important to check patient history of surgeries (looking for abdominal or inguinal surgeries)
- Separate tables for clinical and pathological N
- cN based on size of involved LN; 2 and 5 cm cut points
- pN based on
 - Size of involved LN: 2 and 5 cm cut points
 - Number of involved LNs: 5 is cut point

87

M Categories

- M1 subdivided to distinguish between distant nodal or lung mets and mets to other viscera

88

TNM Fields

- **Case 1:** 1.8 cm Pure seminoma confined to testes; LVI absent. CT abdomen/pelvis negative
- **Case 2:** 5 cm and 2.7 cm mixed germ cell tumors confined to testes; LVI indeterminate
- **Case 3:** 9.5 cm mixed germ cell tumor confined to testes; LVI present: post-op scans show involved RLNs (para-aortic and aortocaval), as well as mets to distant LNs (retrocrural and subcarinal/paraesophageal) and bilateral lung mets

89

Clinical AJCC TNM Categories

T N M

- Case 1 _____ _____ _____
- Case 2 _____ _____ _____
- Case 3 _____ _____ _____

90

Pathological AJCC TNM Categories

	T	N	M
• Case 1	_____	_____	_____
• Case 2	_____	_____	_____
• Case 3	_____	_____	_____

91

Tumor Markers

<ul style="list-style-type: none"> • Pre-op markers <ul style="list-style-type: none"> • May suggest histo types of tumor (Example: seminomas do not produce AFP) • May be used by urologists to request further path specimens • Used for clinical group stage 	<ul style="list-style-type: none"> • Post-op markers <ul style="list-style-type: none"> • Residual? If markers do not return to normal in appropriate time, discuss adjuvant therapy (chemo, RT) • Recurrence? After normal labs then markers start rising • Used for pathological stage
--	---

92

Recording Lab Values when “less than” or “greater than” are used

- Record the lab value as **one less** than stated when a value is reported as “less than X.”
 - Example 1: PSA stated as < 5. Record 4.9
 - Example 2: hCG lab value resulting findings of <1. Record 0.9
 - Example 3: ER Percent Positive stated as < 60%. Record 059 (59%)
- Record the value as **one more** than stated when value is reported as “more than X.”
 - Example 1: CEA stated as > 7. Record 7.1
 - Example 2: PR Percent Positive > 75%. Record 076 (76%)

Per General Instructions (updated with Version 1.5 January 2019)

93

Serum Markers (S) - Notes

- Code S per MD; MD statement takes priority over any S value determined by available lab values or calculated by vendor software
- For AFP: 1 ug/L = 1 ng/ml = **0.83 IU/mL**
- Code clinical S prior to any treatment
- Code pathological S post-orchietomy
 - If post-orchietomy remains elevated, use lowest post-orchietomy value prior to adjuvant therapy
- All 3 lab values are needed for S0-S1. Only 1 elevated test is needed to assign S2-S3. If any individual test is N/A and none of the available tests meets the S2-S3 criterion for that test, assign code 9 (SX).

Serum Markers (S) Clinical and Pathological

Code	Description
0	S0: Marker study levels within normal levels
1	S1: At least one of these values is elevated AND LDH less than 1.5 x N* AND hCG (mIU/L) less than 5,000 AND AFP (ng/mL) less than 1,000
2	S2: LDH 1.5 x N* to 10 x N* OR *hCG (mIU/L) 5,000 to 50,000 OR *AFP (ng/mL) 1,000 to 10,000
3	S3: Only one elevated test is needed LDH greater than 10 x N* OR hCG (mIU/mL) greater than 50,000 OR AFP (ng/mL) greater than 10,000
9	SX: Not documented in medical record S Category Clinical not assessed or unknown if assessed

Serum Markers (S) Fields

	Case 1	Case 2	Case 3
AFP			
Pre	2 ng/mL (0 – 9)	4.7 ng/mL (0 – 8)	83 (H)
Post	Not repeated	3.2 ng/mL (0 – 8)	193 (H)
BhCG			
Pre	< 2 mIU/mL (< 2)	51.48 mIU/mL (< 5000 mIU/mL)	3 mIU/mL (0 – 5)
Post	Not repeated	< 2.39 mIU/mL (0 – 1)	Not repeated
LDH			
Pre	197 units/L (100 – 230)	LDH 1447 IU/L (313 – 618)	293 u/L (100 – 230)
Post	Not repeated	LDH 412 IU/L (313 – 618)	201 (normal)

Serum Markers (S) Clinical and Pathological

	Clinical	Pathological
• Case 1	_____	_____
• Case 2	_____	_____
• Case 3	_____	_____

97

SSDI: AFP Pre-Orchiectomy Lab Value

- MD statement when no other info available
- Record highest AFP lab value prior to orchiectomy or systemic treatment
- ug/L = ng/ml
- **1 ng/mL = 0.83 IU/mL** (to be added to version 1.5)
- Use same lab value for pre-orchiectomy lab value and range
- Level should return to normal < 35 days after surgery
- False + with liver diseases

98

AFP Conversion from IU/mL to ng/mL

- Per the Canswer Forum 11/1/18
<http://cancerbulletin.facs.org/forums/forum/site-specific-data-items-grade-2018/84739-testis-ch-59-afp-conversion-from-iu-ml-to-ng-ml>
- This will be added to the SSDI manual for the 2019 update.
- From the ADVIA Centaur Assay Manual for AFP: The system reports AFP results in ng/mL (common units) or IU/mL (SI units), depending on the units defined when setting up the assay.
- **The conversion formula is 1 ng/mL = 0.83 IU/mL.**

99

SSDI: AFP Pre-Orchiectomy Lab Value

Code	Description
0.0	0.0 nanograms/milliliter (ng/mL)
0.1-99999.9	0.1 - 99,999.9 ng/mL
XXXXX.1	100,000 ng/mL or greater
XXXXX.7	Test ordered, results not in chart
XXXXX.8	Not applicable: Information not collected for this case
XXXXX.9	Not documented in medical record AFP Pre-Orchiectomy not assessed or unknown if assessed

100

SSDI: AFP Post-Orchiectomy Lab Value

- MD statement when no other info available
- Record highest AFP lab value after orchiectomy but prior to adjuvant treatment
- If post-orchiectomy remains elevated, use lowest post-orchiectomy value prior to adjuvant therapy
- ug/L = ng/ml
- **1 ng/mL = 0.83 IU/mL** (to be added to version 1.5)
- Use same lab value for pre-orchiectomy lab value and range

101

SSDI: AFP Post-Orchiectomy Lab Value

Code	Description
0.0	0.0 nanograms/milliliter (ng/mL)
0.1-99999.9	0.1 - 99,999.9 ng/mL
XXXXX.1	100,000 ng/mL or greater
XXXXX.7	Test ordered, results not in chart
XXXXX.8	Not applicable: Information not collected for this case
XXXXX.9	Not documented in medical record AFP Post-Orchiectomy not assessed or unknown if assessed

102

SSDI: AFP Pre-Orchiectomy Range

- MD statement when no other info available
- Record range of highest AFP prior to orchiectomy or systemic treatment
- ug/L = ng/ml
- Use same lab value for pre-orchiectomy lab value and rang

103

SSDI: AFP Pre-Orchiectomy Range

Code	Description
0	Within normal limits
1	Above normal and less than 1,000 nanograms/milliliter (ng/mL)
2	1,000 -10,000 ng/mL
3	Greater than 10,000 ng/mL
4	Pre-Orchiectomy alpha fetoprotein (AFP) stated to be elevated
7	Test ordered, results not in chart
8	Not applicable: Information not collected for this case
9	Not documented in medical record AFP Pre-Orchiectomy Range not assessed or unknown if assessed

104

SSDI: AFP Post-Orchiectomy Range

- MD statement when no other info available
- Record range of highest AFP after orchiectomy but prior to adjuvant treatment
- If post-orchiectomy remains elevated, use lowest post-orchiectomy value prior to adjuvant therapy
- ug/L = ng/ml
- Use same lab value for pre-orchiectomy lab value and rang

105

SSDI: AFP Post-Orchiectomy Range

Code	Description
0	Within normal limits
1	Above normal and less than 1,000 nanograms/milliliter (ng/mL)
2	1,000 -10,000 ng/mL
3	Greater than 10,000 ng/mL
4	Post-Orchiectomy alpha fetoprotein (AFP) stated to be elevated
7	Test ordered, results not in chart
8	Not applicable: Information not collected for this case
9	Not documented in medical record AFP Post-Orchiectomy Range not assessed or unknown if assessed

106

Serum Markers

	Case 1	Case 2	Case 3
AFP			
Pre	2 ng/mL (0 – 9)	4.7 ng/mL (0 – 8)	83 (H)
Post	Not repeated	3.2 ng/mL (0 – 8)	193 (H)
BhCG			
Pre	< 2 mIU/mL (< 2)	51.48 mIU/mL (< 5000 mIU/mL)	3 mIU/mL (0 – 5)
Post	Not repeated	< 2.39 mIU/mL (0 – 1)	Not repeated
LDH			
Pre	197 units/L (100 – 230)	LDH 1447 IU/L (313 - 618)	293 u/L (100 – 230)
Post	Not repeated	LDH 412 IU/L (313 – 618)	201 (normal)

107

SSDI: AFP Pre and Post Orchiectomy Fields

	<u>Pre-Orchiectomy</u>		<u>Post-Orchiectomy</u>	
	Value	Range	Value	Range
• Case 1	_____	_____	_____	_____
• Case 2	_____	_____	_____	_____
• Case 3	_____	_____	_____	_____

108

Beta Human Chorionic Gonadotropin

- Not detectable in healthy males (produced during pregnancy)
- 90% of level every 21 days should be noted during chemo
 - If not, residual? Drug resistance?
- False + from low testosterone or marijuana use
- Elevated in chorioca (100%), embryonal (60%), teratoca (55%)

109

SSDI: hCG Pre-Orchiectomy Lab Value

- MD statement when no other info available
- Record highest hCG after orchiectomy but prior to adjuvant treatment
- IU/L = mIU/ml
- Use same lab value for post-orchiectomy lab value and range

110

SSDI: hCG Pre-Orchiectomy Lab Value

Code	Description
0.0	0.0 milli-International Units/milliliter (mIU/mL)
0.1-99999.9	0.1 - 99,999.9 mIU/mL
XXXXX.1	100,000 mIU/mL or greater
XXXXX.7	Test ordered, results not in chart
XXXXX.8	Not applicable: Information not collected for this case
XXXXX.9	Not documented in medical record hCG Pre-Orchiectomy Lab Value not assessed or unknown if assessed

111

SSDI: hCG Post-Orchiectomy Lab Value

- MD statement when no other info available
- Record highest hCG after orchiectomy but prior to adjuvant treatment
- If post-orchietomy remains elevated, use lowest post-orchietomy value prior to adjuvant therapy
- IU/L = mIU/ml
- Use same lab value for post-orchietomy lab value and range

112

SSDI: hCG Post-Orchiectomy Lab Value

Code	Description
0.0	0.0 milli-International Units/milliliter (mIU/mL)
0.1-99999.9	0.1 - 99,999.9 mIU/mL
XXXXX.1	100,000 mIU/mL or greater
XXXXX.7	Test ordered, results not in chart
XXXXX.8	Not applicable: Information not collected for this case
XXXXX.9	Not documented in medical record hCG Post-Orchiectomy Lab Value not assessed or unknown if assessed

113

SSDI: hCG Pre-Orchiectomy Range

- MD statement when no other info available
- Record range of highest hCG prior to orchiectomy or systemic treatment
- IU/L = mIU/ml
- Use same lab value for pre-orchietomy lab value and range

114

SSDI: hCG Pre-Orchiectomy Range	
Code	Description
0	Within normal limits
1	Above normal and less than 5,000 milli-International Units/milliliter (mIU/mL)
2	5,000 - 50,000 mIU/mL
3	Greater than 50,000 mIU/mL
4	Pre-orchiectomy human chorionic gonadotropin (hCG) stated to be elevated
7	Test ordered, results not in chart
8	Not applicable: Information not collected for this case
9	Not documented in medical record hCG Pre-Orchiectomy range not assessed or unknown if assessed

- SSDI: hCG Post-Orchiectomy Range**
- MD statement when no other info available
 - Record range of highest hCG after orchiectomy but prior to adjuvant treatment
 - If post-orchiectomy remains elevated, use lowest post-orchiectomy value prior to adjuvant therapy
 - IU/L = mIU/ml
 - Use same lab value for post-orchiectomy lab value and range

SSDI: hCG Post-Orchiectomy Range	
Code	Description
0	Within normal limits
1	Above normal and less than 5,000 milli-International Units/milliliter (mIU/mL)
2	5,000 - 50,000 mIU/mL
3	Greater than 50,000 mIU/mL
4	Pre-orchiectomy human chorionic gonadotropin (hCG) stated to be elevated
7	Test ordered, results not in chart
8	Not applicable: Information not collected for this case
9	Not documented in medical record hCG Post-Orchiectomy range not assessed or unknown if assessed

HCG Fields

	Case 1	Case 2	Case 3
AFP			
Pre	2 ng/mL (0 – 9)	4.7 ng/mL (0 – 8)	83 (H)
Post	Not repeated	3.2 ng/mL (0 – 8)	193 (H)
BhCG			
Pre	< 2 mIU/mL (< 2)	51.48 mIU/mL (< 5000 mIU/mL)	3 mIU/mL (0 – 5)
Post	Not repeated	< 2.39 mIU/mL (0 – 1)	Not repeated
LDH			
Pre	197 units/L (100 – 230)	LDH 1447 IU/L (313 -618)	293 u/L (100 – 230)
Post	Not repeated	LDH 412 IU/L (313 – 618)	201 (normal)

118

SSDI: hCG Pre and Post Orchiectomy Fields

	<u>Pre-Orchiectomy</u>		<u>Post-Orchiectomy</u>	
	Value	Range	Value	Range
• Case 1	_____	_____	_____	_____
• Case 2	_____	_____	_____	_____
• Case 3	_____	_____	_____	_____

119

Histo & Tumor Markers

TYPE	FREQ %	AFP %	HCG %
Germ cell	100	50-75	40-60
Seminoma	42	0	9
Non-sem germ	58	65	56
Embryonal	26	70	60
Teratocarcinoma	26	64	57
Teratoma	5	37	25
Choriocarcinoma	1	0	100
Yolk sac	< 1	75	25

www.aafp.org 120

SSDI: LDH Pre-Orchiectomy Range

- MD statement when no other info available
- Record range of highest LDH prior to orchiectomy or systemic treatment
- Test indicates some type of tissue damage – called non-specific marker in 8th ed. AJCC
- Elevated in 50% patients
- Any tumor can elevate LDH

121

LDH Elevation Causes

- Hemolytic anemia
- Pernicious anemia
- Infections
- Sepsis
- Intestinal or lung infarction
- Acute kidney disease
- Acute liver disease
- Acute muscle injury
- Pancreatitis
- Bone fractures
- Testicular cancer, lymphoma, OR other cancers
- Strenuous exercise
- Increased platelet count

122

SSDI: LDH Pre-Orchiectomy Range

Code	Description
0	Within normal limits
1	Less than 1.5 x N (Less than 1.5 times the upper limit of normal for LDH)
2	1.5 to 10 x N (Between 1.5 and 10 times the upper limit of normal for LDH)
3	Greater than 10 x N
4	Pre-Orchiectomy LDH range stated to be elevated
7	Test ordered, results not in chart
8	Not applicable: Information not collected for this case
9	Not documented in medical record LDH Pre-Orchiectomy Range not assessed or unknown if assessed

123

SSDI: LDH Post-Orchiectomy Range

- MD statement when no other info available
- Record range of highest LDH after orchiectomy but prior to adjuvant treatment
- If post-orchiectomy remains elevated, use lowest post-orchiectomy value prior to adjuvant therapy
- LDH is least specific of the 3 tumor markers for testicular cancer; magnitude of LDH elevation directly correlates with testis tumor burden
- If pre-orchiectomy LDH was normal, post-orchiectomy LDH may not be performed: use code 9

124

SSDI: LDH Post-Orchiectomy Range

Code	Description
0	Within normal limits
1	Less than 1.5 x N (Less than 1.5 times the upper limit of normal for LDH)
2	1.5 to 10 x N (Between 1.5 and 10 times the upper limit of normal for LDH)
3	Greater than 10 x N
4	Post-Orchiectomy LDH range stated to be elevated
7	Test ordered, results not in chart
8	Not applicable: Information not collected for this case
9	Not documented in medical record LDH Post-Orchiectomy Range not assessed or unknown if assessed

125

LDH Fields

	Case 1	Case 2	Case 3
AFP			
Pre	2 ng/mL (0 – 9)	4.7 ng/mL (0 – 8)	83 (H)
Post	Not repeated	3.2 ng/mL (0 – 8)	193 (H)
BhCG			
Pre	< 2 mIU/mL (< 2)	51.48 mIU/mL (< 5000 mIU/mL)	3 mIU/mL (0 – 5)
Post	Not repeated	< 2.39 mIU/mL (0 – 1)	Not repeated
LDH			
Pre	197 units/L (100 – 230)	LDH 1447 IU/L (313 – 618)	293 u/L (100 – 230)
Post	Not repeated	LDH 412 IU/L (313 – 618)	201 (normal)

126

SSDI: LDH Pre and Post Orchiectomy Fields

	Pre	Post
• Case 1	_____	_____
• Case 2	_____	_____
• Case 3	_____	_____

127

AJCC Prognostic Stage Group

	Clinical	Pathological	Post Therapy
• Case 1	_____	_____	_____
• Case 2	_____	_____	_____
• Case 3	_____	_____	_____

128

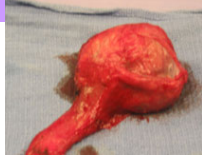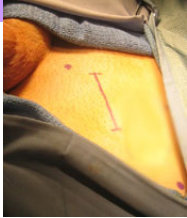TREATMENT

Landmark Advancements in Testicular CA

- 1937 hCG found in male urine CA patients
- 1940s Seminomas radio-sensitive
- 1960 Actinomycin-D chemo in advanced CA
- 1965 Cisplatin found
- 1974 PVB regimen (cisplatin, vinblastine, bleo)
- 1980s nerve-sparing RPLND
- 1987 BEP replaces PVB
- 1989 BEP down to 3 cycles

130

Orchiectomy



www.urologymatch.com

131

Surgery Codes

- 12 Local destruction NOS (no path)
- 20 Local/partial excision
- 30 Orchi WITHOUT spermatic cord
- 40 Orchi WITH cord or NOS if cord
- 80 Orchi NOS

132

... until the fat tenor sings ...

- Doctor watches:
 - Markers
 - CT scans
- to decide whether
 - Chemo
 - RT for LN
 - Observe only
- Takes approx. 3 mos to decide if adjuvant tx



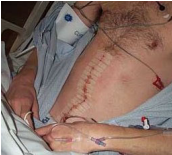133

Surveillance? (sample)

- Year One: Tumor markers & CXR q 2 mo; CT q 3 mos
- Year Two: Tumor markers & CXR q 2 mo; CT q 4 mos
- Years 3-5: Tumor markers, CXR, CT q 6 mos
- After Year 5: Tumor markers, CXR q year

134

Retroperitoneal LN Dissection



Clin Stage	Modified	Nerve-Spare	Full Bilateral
I	Optional	Recom	Not Recom
IIA	Optional	Recom	Not Recom
IIB	Recommended	Possible	Possible
IIC	Not Recom	Possible	Recom

135

Treatment Considerations

- Implants
 - Silicone (firmer?)
 - Saline (softer, more \$)
- Sperm Banking

136

NCCN Treatment: Seminoma

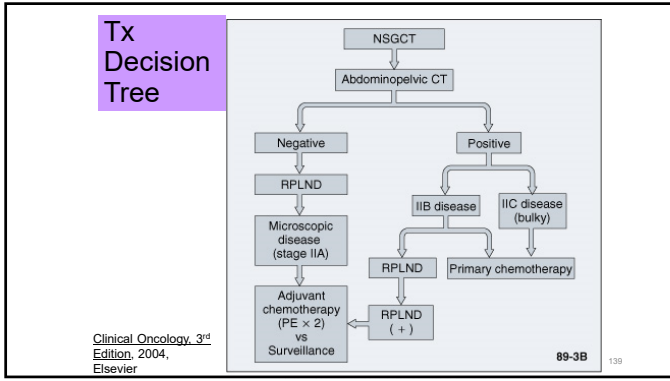
Stage 1	RT to retroperitoneal and ipsilateral inguinal nodes OR Surveillance
Stage 2A	RT to retroperitoneal and inguinal nodes, possibly with mediastinal and supraclavicular nodes OR chemo
Stage 2B, 2C	Platinum-based combination chemotherapy or RT, as in IIA
Stage 3	Platinum-based combination chemotherapy, possibly with resection of residual mass

137

NCCN Treatment: NON-Seminoma

Stage 1A	Surveillance OR nerve-spare RPLND
Stage 1B	Nerve spare RPLND OR chemo OR surveillance (T2 only)
Stage 2A	RPLND OR chemo
Stage 2B, 2C	Chemotherapy OR RPLND
Stage 3	Chemo +/- RPLND

138



First-Line Chemo (per NCI 2018)

- Bleomycin
- Cisplatin
- Cosmegen (dactinomycin)
- Etoposide phosphate
- Ifosfamide
- Vinblastine sulfate
- BEP (bleo, etop, cispl)
- JEB (carbo, etop, bleo)
- PEB (cispl, etop, bleo)
- VeIP (velban, ifos, cispl)
- VIP (etop, ifos, cispl)

140

Survival

Stage	Seminoma	Non-Seminoma	Overall
Stage I	99%	98%	98%
Stage II	95%	95%	95%
Stage III	90%	76%	78%
All Stages			96%

141

Side Effects Post Treatment

- Secondary malignant neoplasms (AML, bladder, kidney, pancreas, rectal, thyroid)
- Pulmonary (especially if bleomycin)
- Cardiovascular toxicity
- Neurotoxicity
- Ototoxicity
- Nephrotoxicity
- Hypogonadism
- Fertility issues

142

Follow-Up

- Most recurrences within first 3 years
- Q 2-3 mos year 1
 - Then q 3-6 mos year 2
 - Then q 6 mos til year 5
- May include PE, lab markers, CXR, CT abd/pel

143

MD-IQ Quiz (NCI PDQ Information)

- Q1: Which of the following statements about testicular cancer is most accurate?
 - A. It most often develops in elderly men
 - B. Most testicular cancers are somatic cell tumors
 - C. It is highly treatable and usually curable
- Q2: Which of the following types is associated with an elevated level of alpha-fetoprotein (AFP) in testicular cancer?
 - A. Seminomas
 - B. Nonseminomas

144

MD-IQ Quiz

- Q3: Which of the following testicular subtypes are considered nonseminomas?
 - A. Embryonal carcinomas
 - B. Teratomas
 - C. Yolk sac tumors
 - D. Choriocarcinomas
 - E. All of the above
- Q4: True or False: Men with nonseminomatous primary tumors appear to have a lower risk of developing subsequent contralateral testis tumors than men with seminomas
 - A. True
 - B. False

145

MD-IQ Quiz

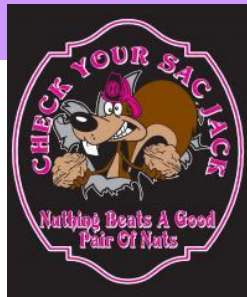- Q5: Which of the following is the procedure of choice to diagnose and treat a malignant testicular mass?
 - A. Trans-scrotal biopsy
 - B. Biopsy of the retroperitoneal lymph nodes
 - C. Radical inguinal orchiectomy with initial high ligation of the spermatic cord

MD-IQ Quiz Editors (imn-newsletters@flmdiq.com)

146

Slogans/Campaigns

- Get a Grip!
- Eyes down, check your balls
- Bollocks to cancer
- Balls in my court
- Cancer stole my left Nut
- So long Mr Right
- Check your bag
- Let's give the boys a hand



147

Fabulous Prize Winners

1946 NAACCR

Coming UP...

Collecting Cancer Data: Colon
• 02/07/2019

Abstracting and Coding Boot Camp
• 03/07/2019

NAACCR

CE Certificate Quiz/Survey

Phrase

Link
<https://www.surveygizmo.com/s3/4770438/Testis-2019>

NAACCR
